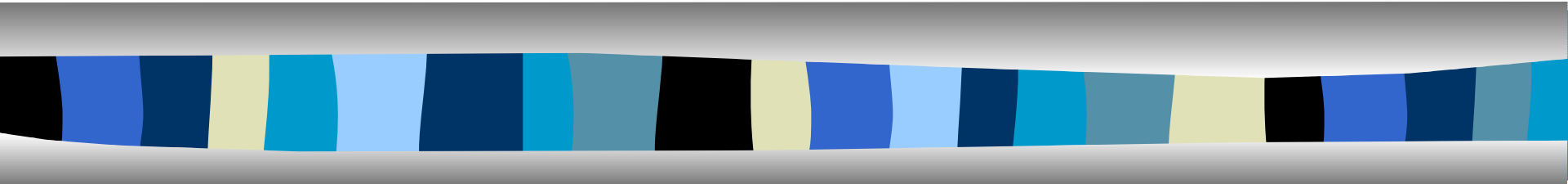


# *iPath Global Network*

Internet platform for distance medical  
collaboration



Kurt Brauchli,  
Monika Hubler  
Basysdata Basel  
Department of Pathology  
University of Basel



# What is iPath ?

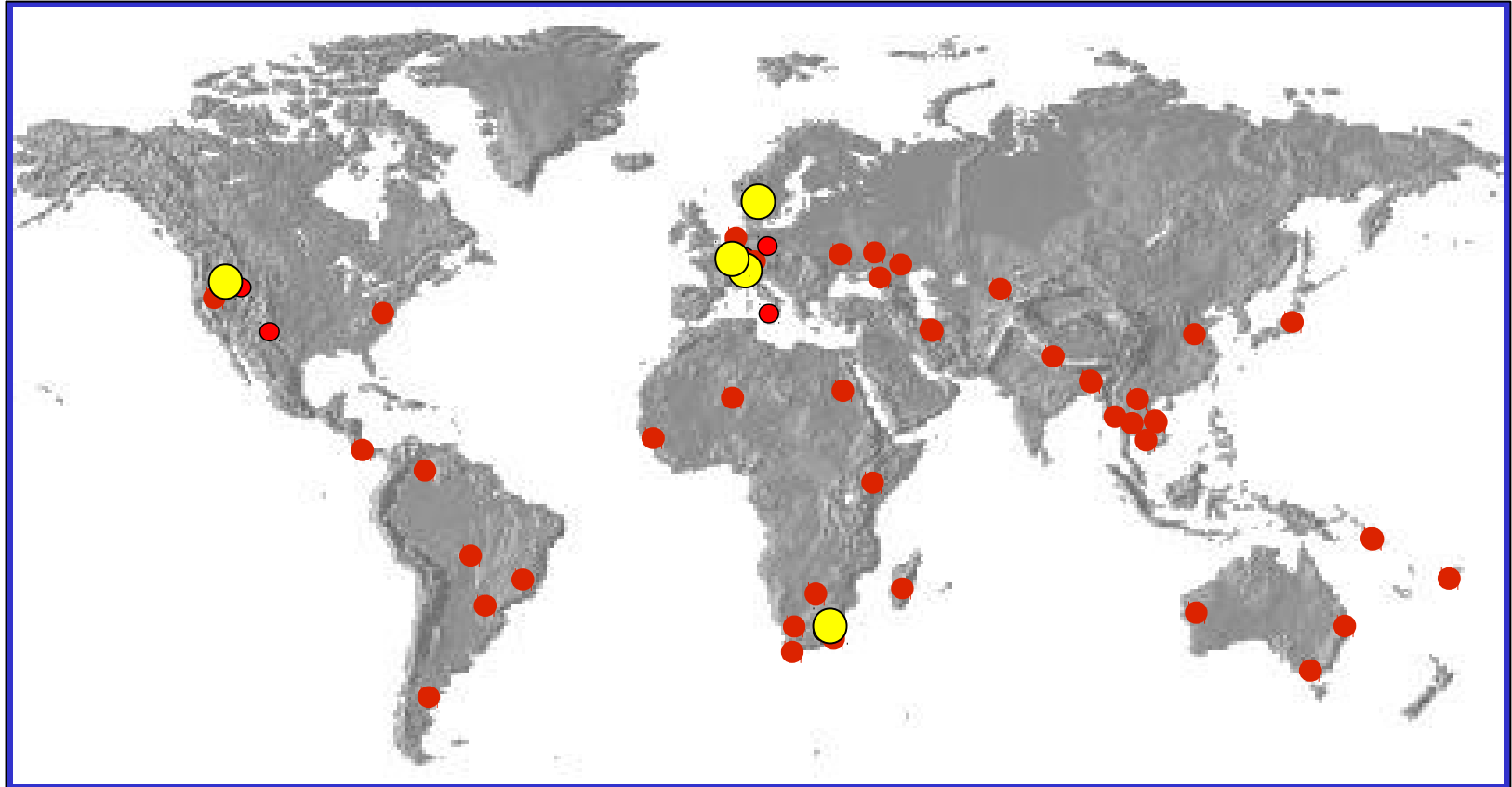
- iPath is an internet platform to facilitate distance collaboration in medical practice, education and research
- Management of medical content such as cases, images, data forms
- Organisation of collaboration in closed user groups: real time and in asynchronous store-and-forward mode



# Sample Applications

- Telepathology consultations from Solomon Islands
- Teledermatology consultations in South Africa
- [dermArena.ch](http://dermArena.ch) - Continuous Education in dermatology in Switzerland

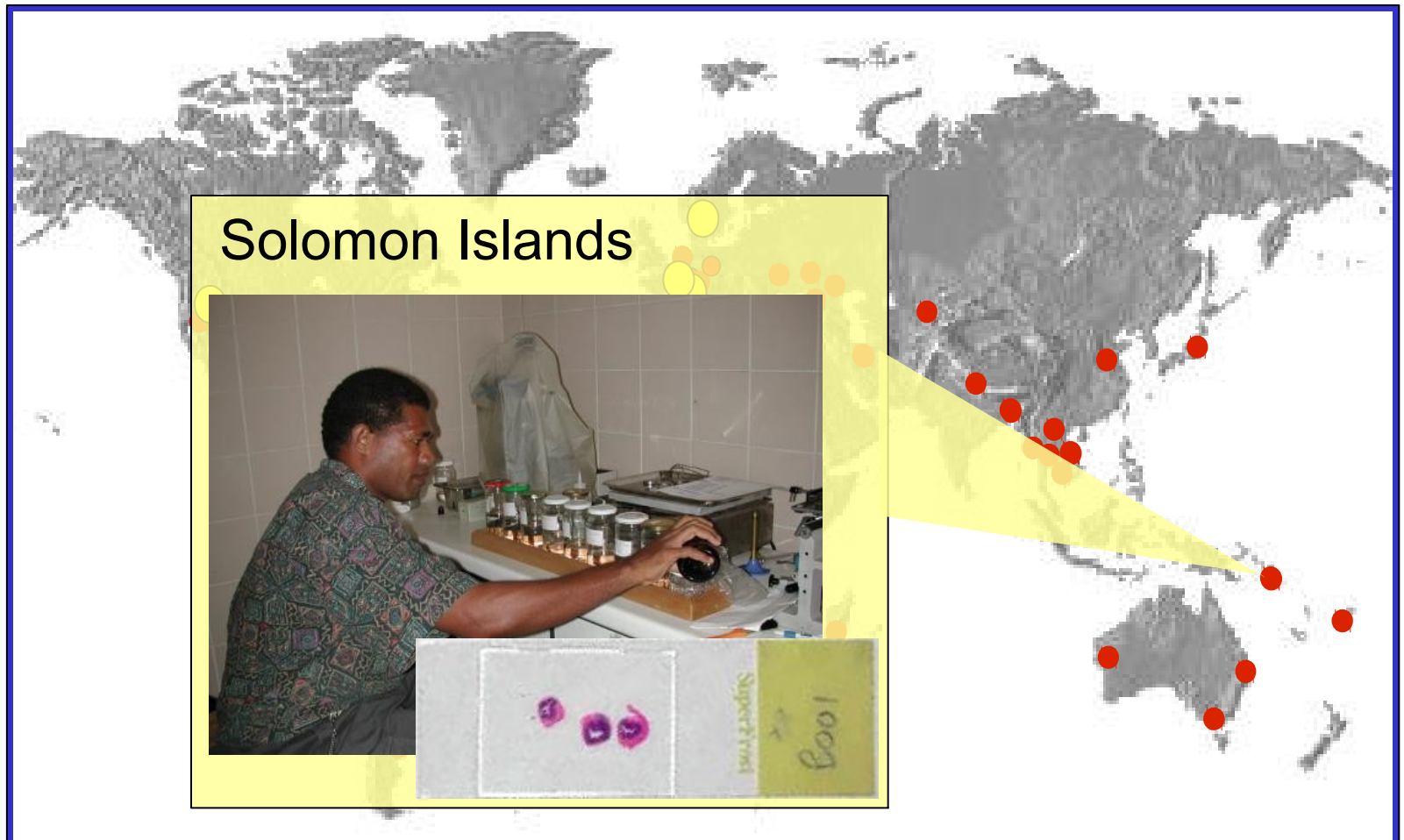
# Global Network



● Utilisateurs

● serveurs

# Telepathology diagnosis

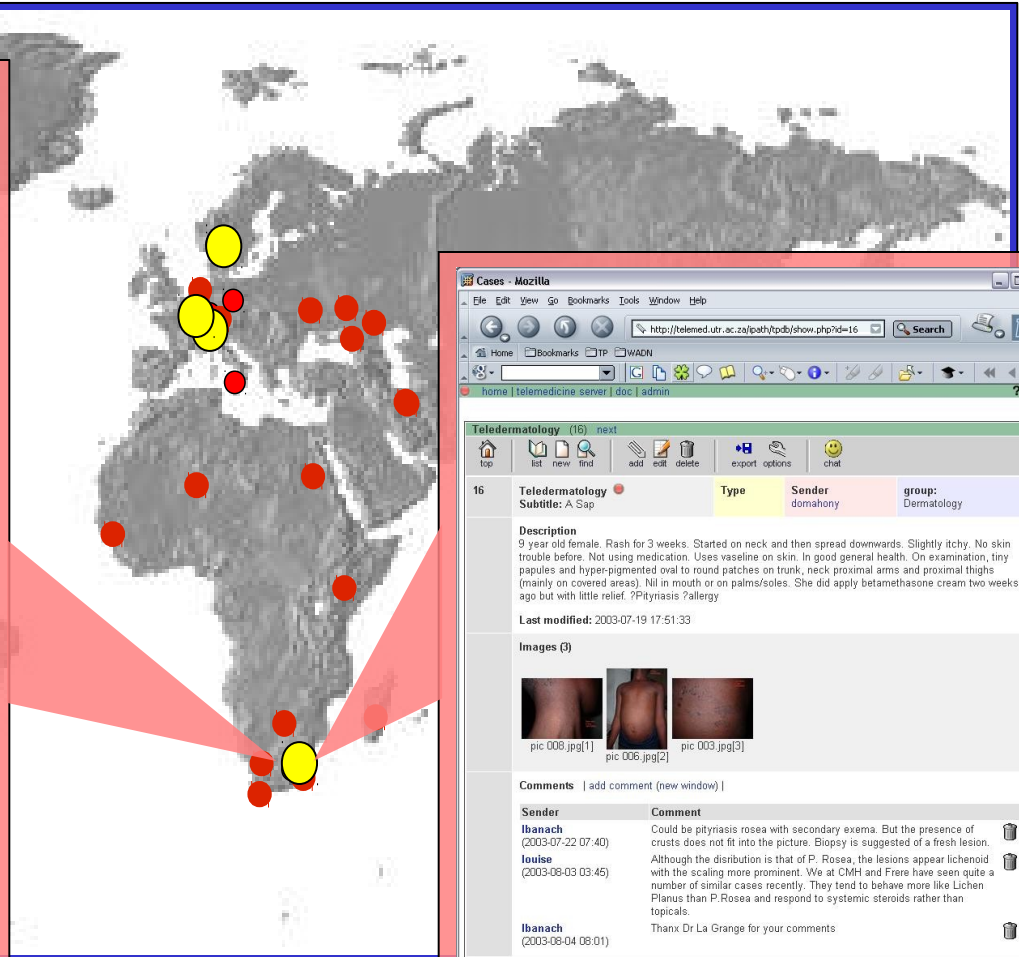
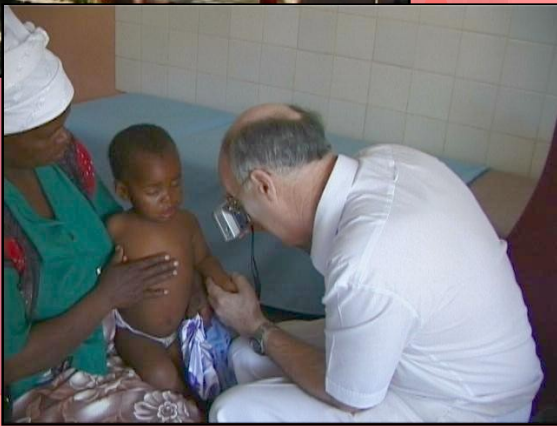

● Utilisateurs

● serveurs

# Tele-Dermatology

## Transkei - South Africa



Cases - Mozilla

http://telemet.utr.ac.za/path/tpdb/show.php?id=16

home | telemedicine server | doc | admin

Teledermatology (16) next

Type	Sender	group:
	domahony	Dermatology

**Description**  
9 year old female. Rash for 3 weeks. Started on neck and then spread downwards. Slightly itchy. No skin trouble before. Not using medication. Uses vaseline on skin. In good general health. On examination, tiny papules and hyper-pigmented oval to round patches on trunk, neck proximal arms and proximal thighs (mainly on covered areas). Nil in mouth or on palms/soles. She did apply betamethasone cream two weeks ago but with little relief. ?Pityriasis ?allergy

Last modified: 2003-07-19 17:51:33

Images (3)

pic 006.jpg[1] pic 006.jpg[2] pic 003.jpg[3]

Comments | add comment (new window) |

Sender	Comment
ibanach (2003-07-22 07:40)	Could be pityriasis rosea with secondary axems. But the presence of crusts does not fit into the picture. Biopsy is suggested of a fresh lesion.
louise (2003-08-03 03:45)	Although the distribution is that of P. Rosea, the lesions appear lichenoid with the scaling more prominent. We at CMH and Frere have seen quite a number of similar cases recently. They tend to behave more like Lichen Planus than P. Rosea and respond to systemic steroids rather than topicals.
ibanach (2003-08-04 08:01)	Thank Dr La Grange for your comments

● Utilisateurs

● serveurs

# Multi-discipline collaboration

## Tumourboard meeting

Lörrach (Germany) + Basel (Switzerland)

LOE\_20060504\_4 (84243)

Home List Find Edit Add Delete print Chat Image drop Export Slideshow Compare referral

**LOE\_20060504\_4** Type: **Sender:** 2006-04-24 14:39  
**Subtitle:** Magen, gastrointestinaler Stromatumor, GIST **glienke** Oncology Center Lörrach

Gastrointestinaler Stromatumor an der Cardialippe, 7mm, Mitoserate <1%. Status nach bioptischer Entfernung mit schwerer Nachblutung und Notfalllaparotomie sowie Thoraxdrainage.

Frage an die Pathologie: Demonstration des Befundes.

Frage an die Internistische Onkologie: Ist eine chirurgische `Nachresektion` zu empfehlen? Wäre alternativ eine Beobachtung erlaubt?

Beschluß der Tumorkonferenz

Aufgrund des sehr niedrigen Risikos (<2cm, Mitoserate <1%) ist eine Beobachtung zu empfehlen. Die erste endosonographische Kontrolle sollte nach abgeschlossener Wundheilung als Ausgangs-befund

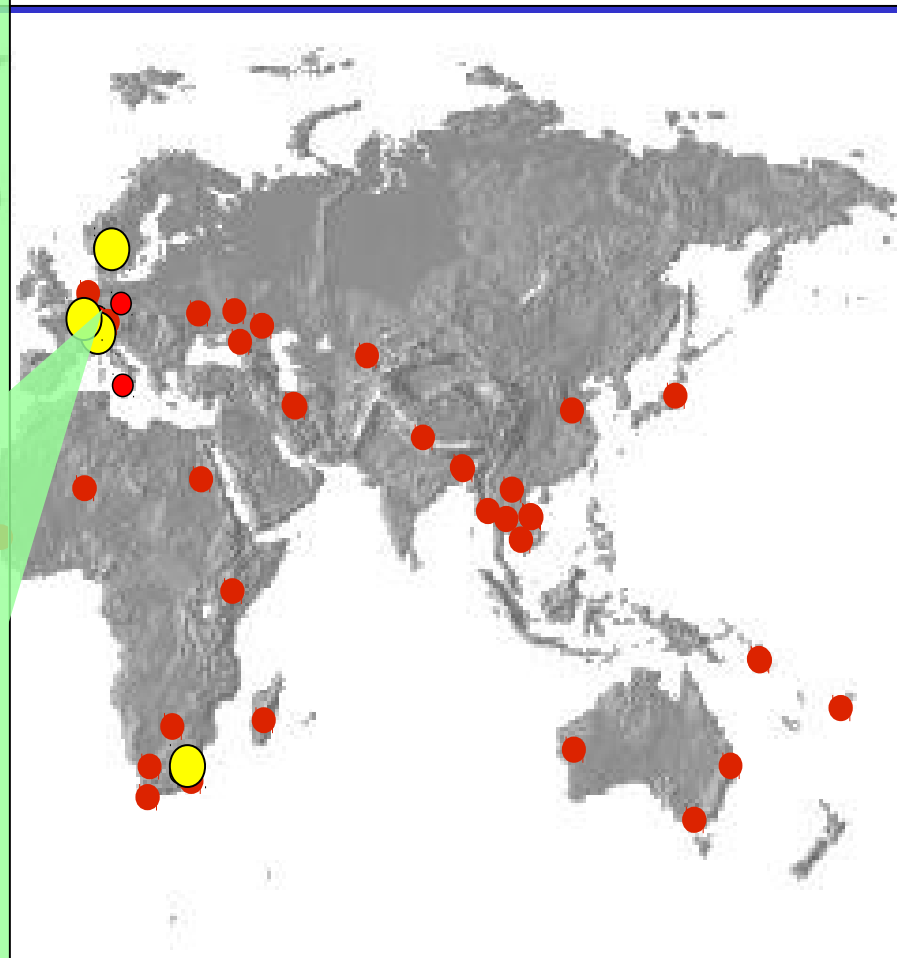
### Gallery:

**Prognostic Features of Gastrointestinal Stromal Tumors**

Parameter	Low Risk	Intermediate Risk	High Risk
Size of Primary	< 2 cm	2-5 cm	> 5 cm
Mitotic Rate at Primary	low	low	medium

**Gastrointestinaler Stromatumor**

- In Abhängigkeit von Risikofaktoren sind Lager- und Tumorkontrolle die Strategie zur Überwachungs- und Kontrollstrategie.
- Eine eventuelle Laparotomie ist ohne Operationen über retroperitoneale Massen eine Entscheidung über Patienten diskutiert werden werden.
- DSCN8233: Med. Klinik St. Lukaskrankenhaus Universität München



# Presentations

iPath INCTR - Mozilla Firefox

Datei Bearbeiten Ansicht Chronik Lesezeichen Extras Hilfe

https://www.ipath-network.com/inctr/presentation/master/359

UBS - UBS e-banking i... The World Clock - Tim... JUNGFRAU 2010 iPath User Manual iPath iTeach LEO Google Mail humonk... Telenet: Inbox http://www.ipath-net... INCTR Branches and ...

iPath INCTR

iPath INCTR - PPT for Presentations - Mozilla Firefox

https://www.ipath-network.com/inctr/object/view/20254

Meistbesuchte Seiten Erste Schritte Aktuelle Nachrichten iPath INCTR Hausen u' Götschak... iPath Verein zur Förd... LEO Deutsch-Englisch

iPath INCTR - PPT for Presentations

English

**hubler**

- Logout
- my groups
- My account
- Preferences
- Alerts

**iPath**

- Home
- Discussion group
- Find case presentations

**Admin**

- User list
- Group settings
- Administration

**Site statistics**

- Active users: 358
- Groups: 9
- Server statistics
- group statistics

Home List Find Edit Add Delete Compare Export Import Chat Slideshow presentatio image drop

**PPT for Presentations** Type: hublerm Sender: hublerm

**Subtitle:** Several topics

- 1.)Diagnostic Findings Bone marrow
- 2.)Lymphknoten, malignes follikulaeres non-Hodgkin Lymphom
- 3.)General conception of ipath
- 4.)multiple lung nodules of varying sizes

**Gallery:**

- KM DD Myelom.jpg
- KM Lymphome Vert...jpg
- KM Lymphome.jpg
- DD MDS MPD.jpg
- DSCN5136.JPG
- DSCN5137.JPG
- DSCN5138.JPG
- DSCN5139.JPG
- DSCN5140.JPG

connected

disable video broadcast

tip: click on the bar to the right to close this toolbox

slide 1

chat (hubler):

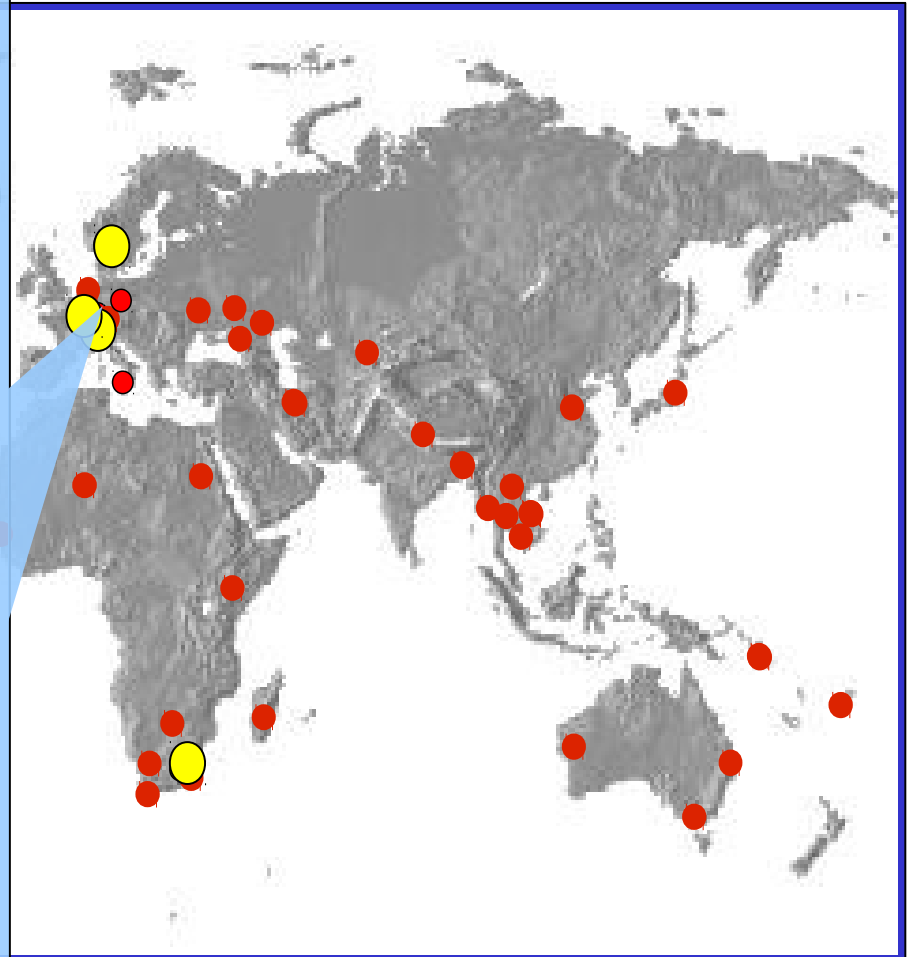
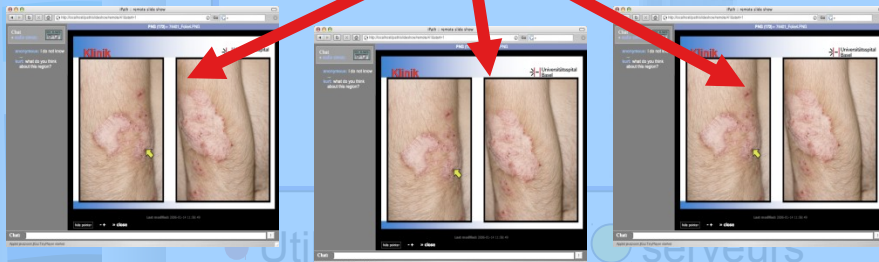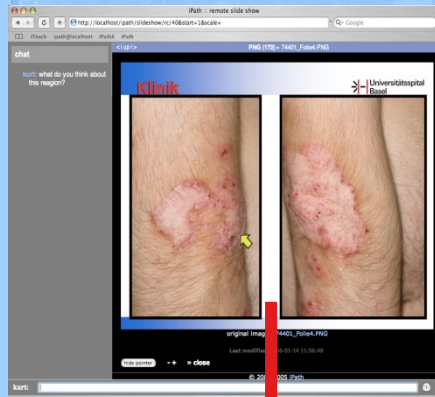hide c



# iPath in dermatology education

## dermArena.ch - Switzerland

Live broadcast of dermatology lectures and seminars (voice + slides)





# Consultation

- **Step 1:** submission or publishing of case and images
  - Email
  - www form
- **Step 2:** Expert discussion - comments and diagnosis by consultants
- **Step 3:** Automatic Feedback to submitter of case

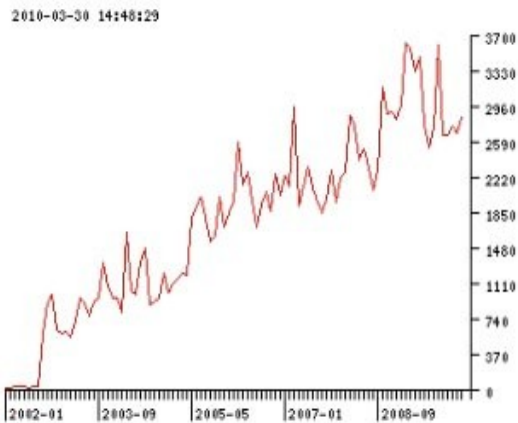
# General Statistics about this server 2002-2010

## General statistics about this server

### user & group statistics

- **active users:** 4249 (total: 6144)
- **groups:** 379 (hidden: 103)

### monthly login statistics

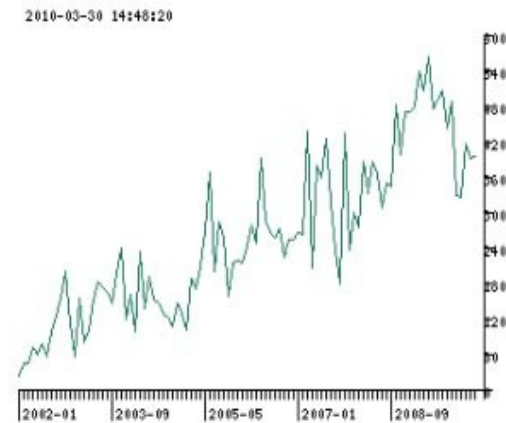


**fig.** Number of logins for every month.  
(numbers are only available since August 2002)

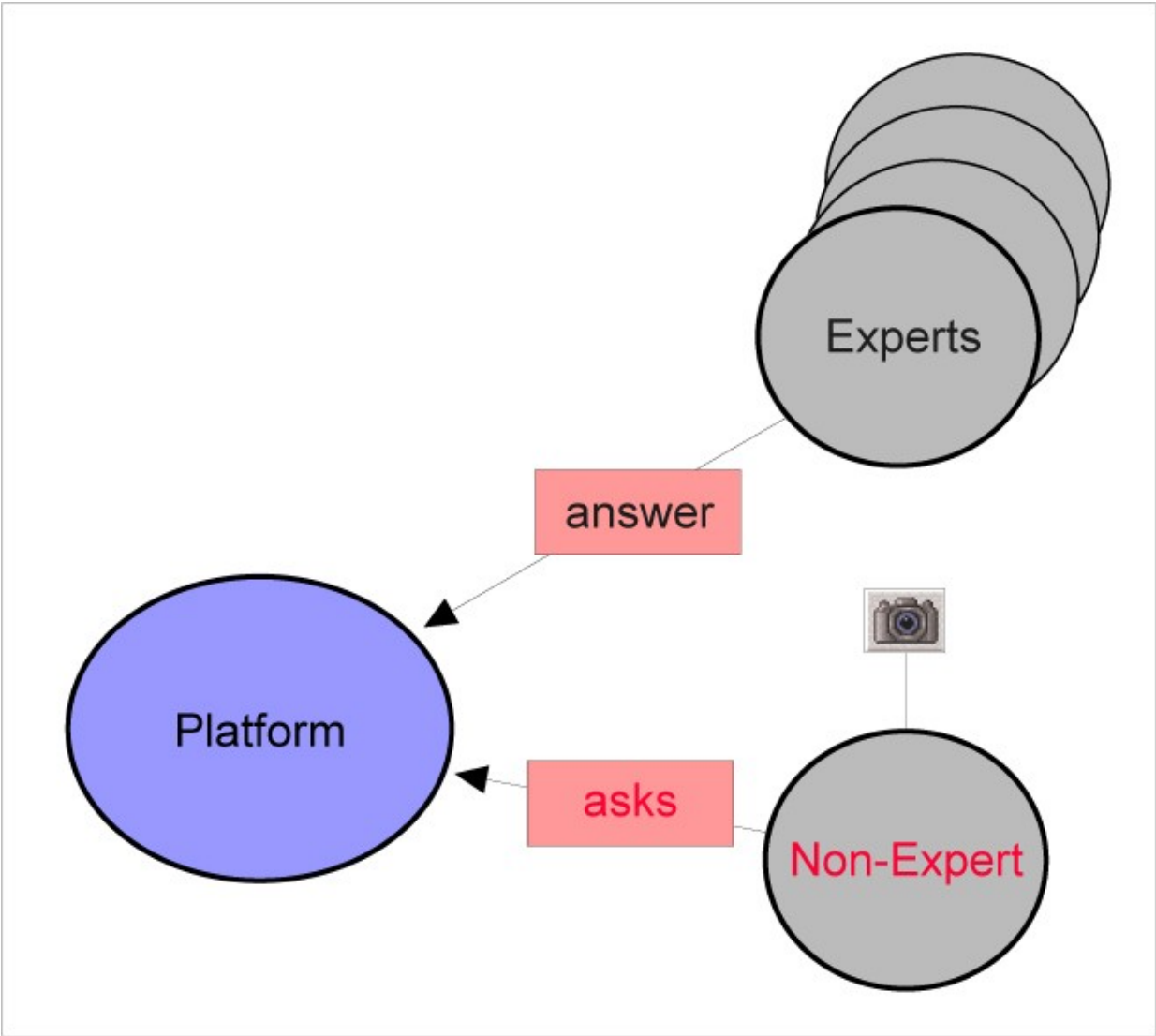
### objects

- **cases:** 25708
- **objects:** audio: 3, blog: 31, dicom: 333, dotslide: 1356, drawing: 249, file: 5485, folder: 2098, form: 12736, forumpost: 18, googleslide: 2, image: 203062, imageseries: 18, link: 1124, news: 84, page: 65, textslide: 4313, video: 229, vmicslide: 3,
- **comments:** 59870

### monthly case statistics



**fig.** Number of cases submitted every month.



# Case Presentation

## - Description & Images

## - Comments/Diagnosis

**New comments:**  
→ automatic email alert



Difficult pregnancy (3391) prev next

top list new find add edit delete export options chat

3391	<b>Difficult pregnancy</b> Subtitle: women with scoliosis	Type question	Sender delwa	group: Ukrainian Swiss Perinatal Health Programme
------	--	------------------	-----------------	--

**Description**  
femal 33years old.Second pregnancy( first pregnancy medical abortion)38-39 weeks.Diagnosis: anatomical small pelvis, Raiter deasis, scoliosis of thoracical and lumbal regions of vertebral columna 4 stage, condition after 7 surgical operations, dislocation of pelvis bones. Bronchial asthma (from 1988)remittens stage,anemia 1 stage.Eclampcy 1 stage.1. In blood analyses: Hb - 101g/l  
2. Echocarddiocscopy: kardiosclerosis, dilatation of right ventricula.What type of delivery do you suggest(cesirion sectio)?What type of anasthesia?How to lead women after operation?

Last modified: 2003-09-24 12:04:11

**Images (4)**

IMGP0013.JPG[1] IMGP0015.JPG[2] IMGP0016.JPG[3] IMGP0019.JPG[4]

**Comments** | add comment (new window) |

Sender	Comment
natal (2003-09-26 06:16)	
raab (2003-09-26 09:10)	[comment sent by email from Martin Raab <martin.raab@unibas.ch>]: Hello Marc and Dimitry, I cannot comment the case but I would like to let you know that I am satisfied that things are moving and that finally your telemedicine group is getting active. Certainly we have to get more specialists online now in order to contribute and to make our initiative effective and useful. I contacted Lucas Opitz meanwhile and asked him to join i-path. Please verify if the group members receive e-mail notifications. I talked two days ago to Andrei and he told me that he does not receive the notifications. All the best, Martin
fkr (2003-10-03 11:29)	I poropose to discuss a primary cesarean section (planned) anesthesia: general f. krahenmann



# Content Managed by iPath

- Cases with text description
- Images (400+ image formats)
- Video clips - automatically converted to flash format for easy preview
- Custom forms
- Links to PubMed (literature)
- ... and many more by extending iPath

# Multi-discipline collaboration

## Example: Tumourboard

- Contribution on one patient by different specialists (radiology, pathology, oncology)
- Presentation of Material during meeting with slideshow mode
- Material is accessible before and after real meeting to all participants
- Joint multi-discipline database of interesting cases. For example in Lörrach there are now over 500 tumour patients documented.

LOE\_20060504\_4 (84243) < | up | >

Home List Find Edit Add Delete print Chat Image drop Export Slideshow Compare referral

**LOE\_20060504\_4** Type: **Sender:** 2006-04-24 14:39  
Subtitle: Magen, gastrointestinaler Stromatumor, GIST glienke Oncology Center Lörrach

Gastrointestinaler Stromatumor an der Cardiallippe, 7mm, Mitoserate <1%. Status nach biotischer Entfernung mit schwerer Nachblutung und Notfalllaparotomie sowie Thoraxdrainage.  
Frage an die Pathologie: Demonstration des Befundes.  
Frage an die Internistische Onkologie: Ist eine chirurgische 'Nachresektion' zu empfehlen? Wäre alternativ eine Beobachtung erlaubt?  
Beschluss der Tumorkonferenz  
Aufgrund des sehr niedrigen Risikos (<2cm, Mitoserate <1%) ist eine Beobachtung zu empfehlen. Die erste endosonographische Kontrolle sollte nach abgeschlossener Wundheilung als Ausgangs-befund

**Gallery:**

schm0001.jpg schm0002.jpg schm0003.jpg schm0004.jpg schm0005.jpg

DSCN8233.JPG CD117.JPG Ki-67.JPG BASEL Report Folie5.JPG

Folie6.JPG Folie7.JPG

Prognostic Features of Gastrointestinal Stromal Tumors

Feature	High Risk	Low Risk	Intermediate Risk
Size of Primary	> 2cm	≤ 2cm	> 3 cm
Mitotic Rate of Primary	High	Low	Intermediate

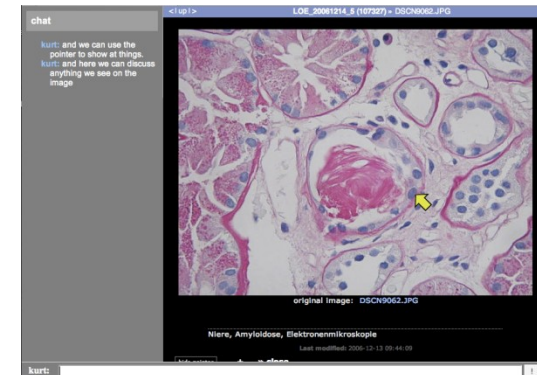
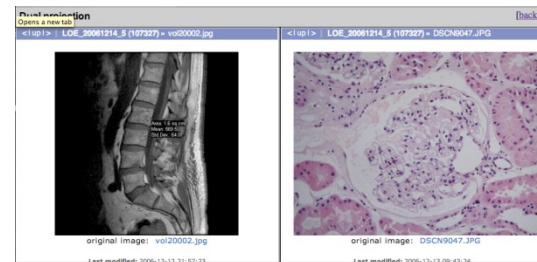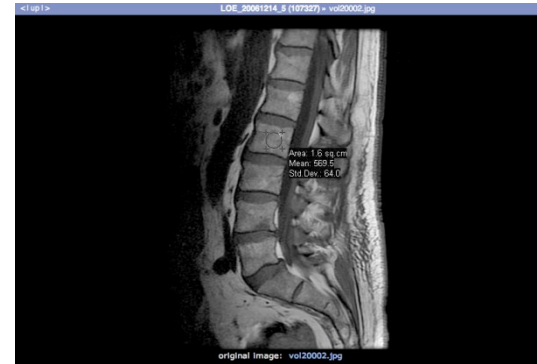Gastrointestinaler Stromatumor

- In Abhängigkeit von Blutgefäßgröße und Lage des Tumors sollte die Strategie zur intraoperativen Blutstillung gewählt werden.
- Eine adjuvante Chemotherapie ist nur bei Stromatomen mit unvollständiger Resektion zu erwägen.
- Die endoskopische Entfernung von GIST Tumoren ist nur bei Tumoren mit einer Größe von < 2 cm und einer Mitoserate von < 1% zu empfehlen.

• DSCN8233: Histologie des Tumors

# Advanced functionality

- Slideshow mode  
slideshow directly from server
- Compare images  
display 2 images next to each other
- Web meeting  
interactive collaboration on  
synchronised set of slides  
(chat + shared pointer)

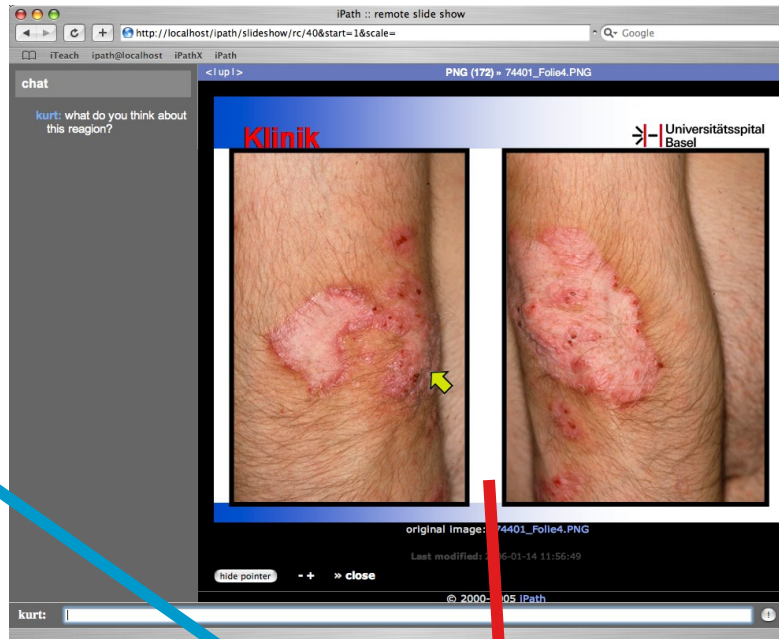




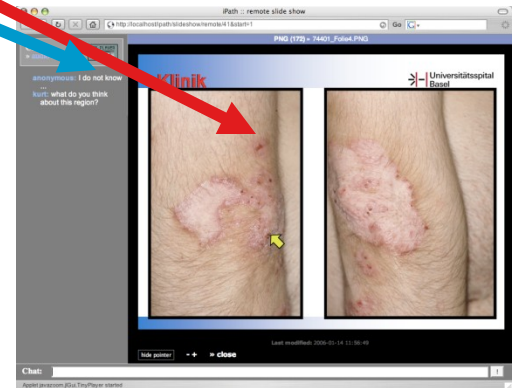
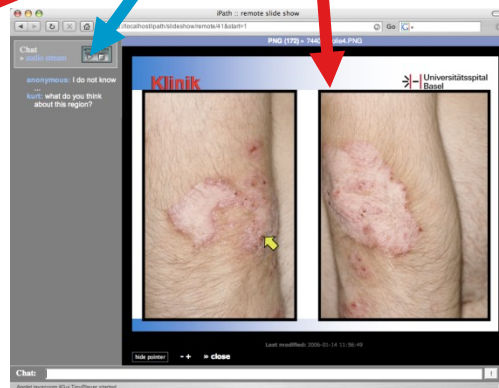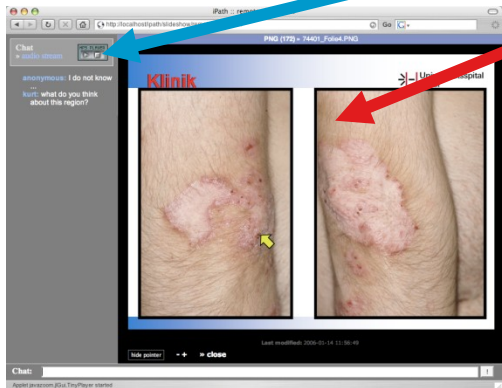# Broadcast of lectures

- Synchronised viewing of slides
- Live broadcast of voice  
over low bandwidth audio streaming (8-24 KB/s)
- Shared pointer (optional)
- Text chat for questions form audience



Streaming Server iPath





# How to use iPath ?

- Basysdata is running a service based on iPath. This is available with low costs to all not-for-profit projects with developing countries
  - <http://www.ipath-network.com>
- iPath software is open source. Anyone can install it and run an independent service.



# Virtual portals

- Sharing one server and one installation of iPath between many institutions
- Custom “corporate identity”  
(front page, settings and layout)
- Shared database of content and user accounts
- Examples at the moment:
  - <http://www.ipath-network.com>
  - <http://telemed.ipath.ch/raft>
  - <http://telemed.ipath.ch/hocmai>
  - <http://telemed.ipath.ch/tanzania>



# More Information

- iPath in action

- <http://www.ipath-network.com>
- [monika.hubler@basysdata.ch](mailto:monika.hubler@basysdata.ch)
- 

- iPath Software

- <http://ipath.sourceforge.net>